

Imaging of the anterolateral instability of the ankle by ultrasound

Hrazdira, L.Skotáková J.

St. Anna's Faculty Hospital in Brno, Orthopedic Department

Summary

This article reviews ten year results of ultrasound examination of the acute and chronic instability of the ankle. A new author's technique of examining the patient is described. In principle, US examination in stressed positions is used. A new ventrolateral approach is contrasted with Ernst's dorsal approach. Through this comparison it is possible to assess the level of instability (talocrural and subtalar joints). US examination eliminates exposure to radiation of both the patient and the physician. It appears to be the optimum screening method for evaluating instability of the ankle.

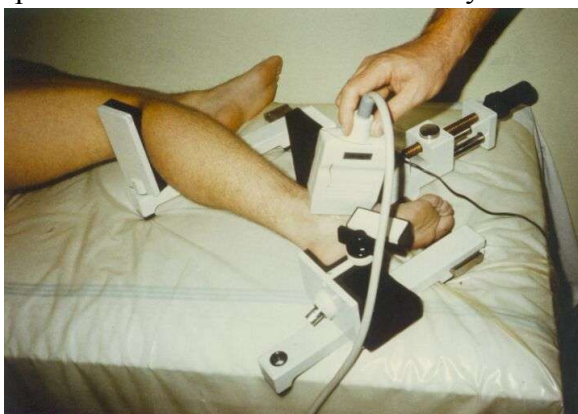
Introduction

Ankle sprains represent a difficult diagnostic and therapeutic problems not only in the athlete but also in non-sportsmen. They result from an initial injury to the lateral-collateral complex including the anterior talofibular, calcaneofibular and posterior talofibular ligaments. (Zwipp, Marc 1,2) Complete rupture of the anterior talofibular ligament (ATFL) alone or in combination with the calcaneofibular ligament (CFL) results in clinically demonstrable instability. Although isolated subtalar instability is unusual, subtalar injury in association with ankle sprain is common (Harper 3). Many individuals have complaints of functional instability after an ankle sprain (Brand 4). The ankle constitutes an anatomical-functional entity in which the same important role is played by the bony structure as well as by the ligaments. It is surprising that currently it is not entirely clear which of the anatomical and functional details refer to ankle stability. The analogical situation in the diagnostic and therapeutic treatment of ankle injuries is not entirely obvious either. Optimum diagnostic and therapeutic procedures are yet to be discovered.

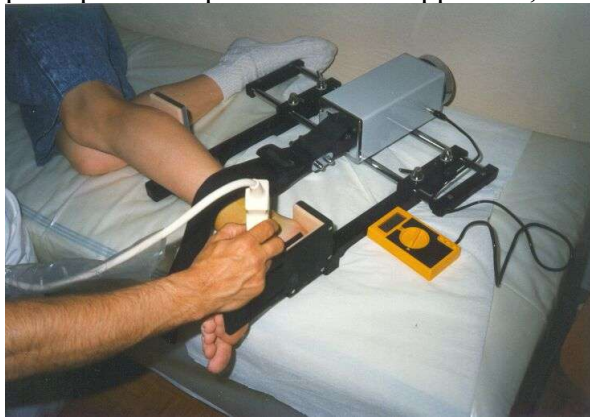A careful clinical examination of the anterior drawer sign and the talar tilt is only the first step in the complex examination of ankle stability. Traditionally, standard X-ray examination is performed as the second step. The next step can be the stress (enforced position) testing – a common mode of assessing ligamentous injury in the athlete. But if the standard X-ray examination is followed by another X-ray, it involves increasing negative side-effects. For this purpose it seems most advantageous to measure the bony distances with the help of ultrasound with regard to the advantage of a non-invasive nature of the examination (Ernst 5), which is best performed under anesthesia (Olson 6).

Methods

The evaluation of stability not only in the talocrural but also in the talocalcaneal joints has a fundamental significance for the therapy of injured ankle. The authors present long-term results of their own method of this examination (Hrazdira 7,8). They have been using ultrasound equipment with 7.5 MHz lineal array (probe) and the apparatus for an enforced position in the method described by Scheuba (fig.1a).

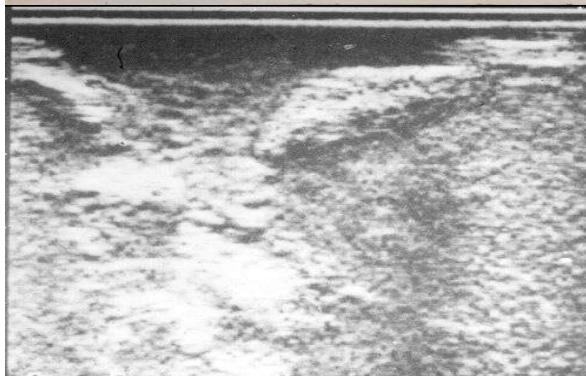
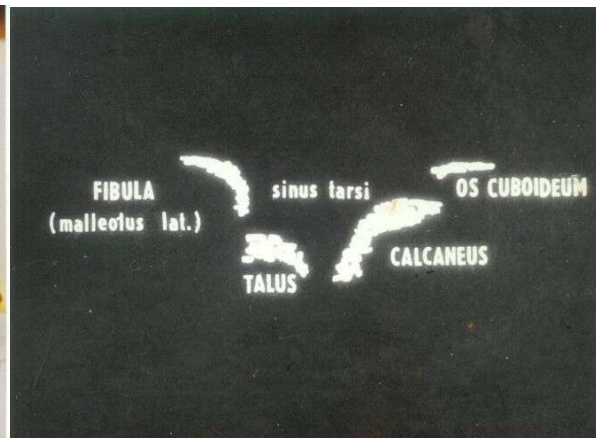
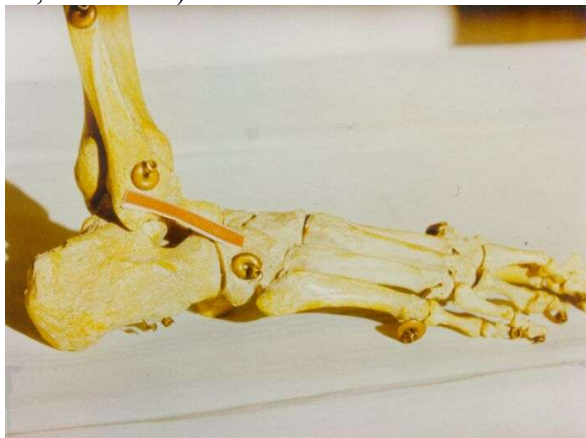


Furthermore, they have been using an apparatus of their own construction based on the same principles. The pressure in this apparatus, however, is replaced by tension (fig.1 b).



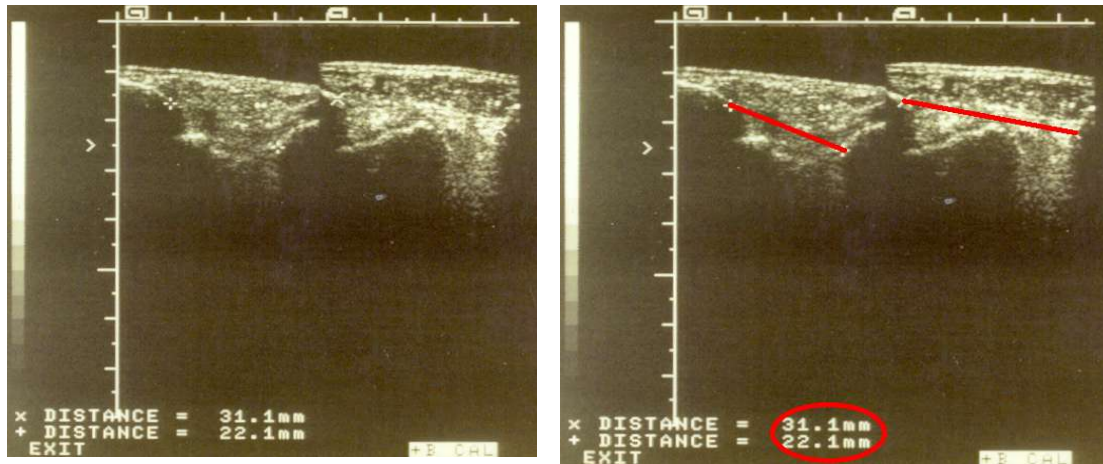
In the standard position, pressure/tension of 250 N is applied (± 50 N according to the constitution and sex of the patient). The introduction of the method into clinical practice was preceded by experimental work with the help of model material – the bony skeleton and freshly amputated legs.

The authors tested the optimal approach on a skeletal model (only bony structures without soft tissues echographically examined in water medium): it is a ventrolateral cut, where it is possible to see the lateral malleolus as well as the calcaneus, the talus can be visible in the deep of the sinus tarsi and in the margin can sometimes be detected the cuboid bone (see fig. 2a, 2b and 2c).

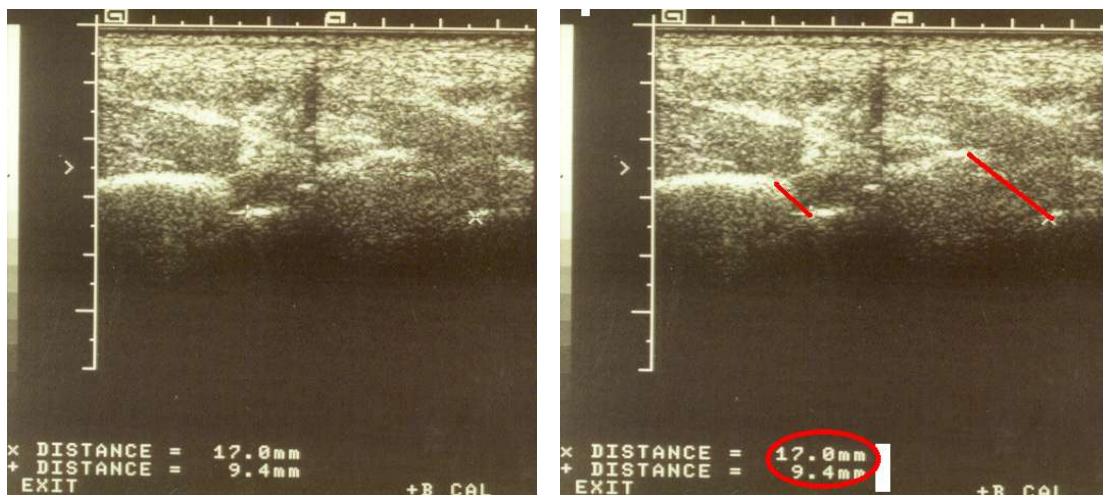

They measured the fibulo-calcaneal distance in both unenforced (quiet) and in enforced (stressed) positions. The results of quiet and stressed positions were compared with those obtained from the contralateral side. Moreover, US scans were supplemented with the history of the patient, which showed individual injuries of both ankles. The reference value used by the authors was based on the correlation with the X-ray examination (Lazarus

M.L.medscisport, Selingson D. 9, Hintermann B. 10). The difference between quiet and stressed position exceeding 3 mm is considered to be indicative of AFTL), more than 7 mm of AFT + CF injury because USG measurement fully correlates with it. The difference (subluxation) of more than 3 mm when compared with the same foot unstressed or in comparison with the contralateral side is considered a positive evidence of instability.



During the following examination, the injury level is determined by ultrasound again. The posterior (dorsal) longitudinal approach according to Ernst and co-authors 1990 (5) is used.



The distance between the tibia (margo posterior) and the talus (trochlea tali) again in the stressed position proves the stability of the talocrural joint. The difference between the ventrolateral and dorsal approach shows the talocalcaneal level as well as the subtalar level of instability. If the difference in both cuts is the same then the talocrural joint is injured, the difference between ventrolateral and dorsal cuts detected the subtalar instability. All examinations are performed in local anesthesia to minimize the influence of external muscle stabilizers as well as with pain-stimulated muscle contraction.

Results

In the period 1991-2001, the authors examined 820 sportsmen aged from 11 to 61. The instability of the ankle was proved in 510 cases. Acute post-traumatic examination performed in 127 cases.

Total number of patients: n=820

Women: n=463

Men: n=357

Positive findings in 510 patients = 62% from the total

Acute instability n = 127 = 25% (60% women, 54 % men)

Chronic instability n = 383 =75% (54 women, 46% men)

	Women				Men			
	talocrural joint		subtalar joint		talocrural joint		subtalar joint	
	n	%	n	%	n	%	n	%
Acute instability	73	58	3	2	46	36	5	4
Chronic instability	195	51	12	3	167	44	9	2

Discussion

The correlation between X-ray and ultrasound examination as well as the correlation between Scheuba's apparatus and the apparatus of our own construction was proved. In both cases identical conclusions have been reached. Post-traumatically no isolated cases of difference in fibulocalcaneal and fibulo-cuboidal diameters have been found. Only small differences in general hyperlaxity have been detected. Postoperative checks are also included in the results. Cases of reinjuries are taken as new cases.

The whole complex of diagnostic steps especially in chronic instability is important for treatment. Stress testing of stability should be only one supporting part. A history of insecurity and instability should be more important in diagnosis than other examinations. According to Freemann's conclusions only 40 % of the patients demonstrating radiological instability will have symptoms of unstable ankle (Freemann 11,12) and approximately the same percentage of patients with symptomatic ankle will be shown to be stable on stress testing (Kristiansen 13).

No isolated calcaneo-cuboid instability has been revealed.

Conclusion

The ultrasound examination in stressed (enforced) positions in ventrolateral approach is very accurate and reproducible screening examination that can fully replace the X-ray examination. It can assess instability of the ankle on both talocrural and subtalar level in acute or chronic cases. It is relatively inexpensive, quick, and at the same time safe, as it does not have any negative side-effects either for the patient or for the examining physician. US of the ankle is the technique of first choice in the examination and evaluation of the subtalar joint, since the use of other methods in this case may be less effective or even problematic.

Key words

Ankle instability – ultrasound examination of stressed positions in talocrural and subtalar joints

References

1. Zwipp, H. Die antero-laterale Rotationinstabilität des Sprunggelenkes. *Hefte zur*

Unfallheilkunde 177-179, 1986

2. Marc R. Safran, Roy S. Benedetti, Arthur R. Bartolozzi III, and Bert R. Mandelbaum. Lateral ankle sprains: a comprehensive review Part 1: etiology, pathoanatomy, histopathogenesis, and diagnosis. *Med. and Science in Sports and Exercise* 7:429-437, 1999
3. Harper, M. C. The lateral ligamentous support of the subtalar joint. *Foot Ankle* 11:354-358, 1991.
4. Brand, R. L., H. M. Black, and J. S. Cox. The natural history of inadequately treated ankle sprains. *Am. J. Sports Med.* 5:248-249, 1977.
5. Ernst, R., Grifka, J., Gritzan, R., Kemen, M., Weber, A.: Sonographische Kontrolle des Außenbandapparates am oberen Sprunggelenk bei der frischen Bandruptur und chronischen Bandinstabilität. *Z. Ortop.* 12:525-530, 1990.
6. Olson, R., W. Arthrography of the ankle: its use in the evaluation of ankle sprains. *Radiology* 92:1439-1446, 1969.
7. Hrazdira, L., Šín, A. Diagnostics and treatment of antero-lateral instability of the ankle in sportsmen. *Hung. Rev. Sports Med.* 33:103-107, 1992
8. Hrazdira, L., Veselý, T. Praktická ultrasonografie v traumatologii a ortopedii, 98-100, 1992
9. Seligson, D., J. Gassman, and M. Pope. Ankle instability: evaluation of the lateral ligaments. *Am. J. Sports Med.* 8:39-42, 1980.
10. Hintermann, B., P. J., Holzach, and P. Matter. Verletzungsmuster des fibularen Bandapparates: radiologische Diagnostik und klinische Studie. [Injury pattern of the lateral ankle ligaments: radiological diagnosis and clinical study] *Unfallchirurg* 95:142-147, 1992.
11. Freeman, M. A. Instability of the foot after injuries to the lateral ligament of the ankle. *J. Bone Joint Surg.* 47-B:669-677, 1965.
12. Freeman, M. A. Treatment of ruptures of the lateral ligament of the ankle. *J. Bone Joint Surg.* 47-B:661-668, 1965
13. Kristiansen, B. Evan's repair of lateral instability of the ankle joint. *Acta Orthop.* 52: 679-682, 1981.